



Prechannel Entrapment of the Ulnary Nerve by an Intermuscular Arcade: The Importance of Ultrasonographic Neurography in the Demonstrating of Compression Site

Ulnar Sinirin İntermusküler Bağ Tarafından Kanal Öncesi Sıkıştırılması: Sıkışma Yerinin Gösterilmesinde Ultrasonografik Nörografinin Önemi

Ulnar Sinir Sıkışmasında Ultrasonografik Nörografi / Ultrasonographic Neurography for Ulnary Nerve Entrapment

Cengiz Çokluk, Enis Kuruoğlu, Abdullah Hilmi Marangoz, Kerametdin Aydın
Ondokuzmayıs University, Medical Faculty, Department of Neurosurgery, Samsun, Turkey

Özet

Amaç: Ultrasonografik nörografi tekniği periferik sinir yaralanmaları ve sıkışma nöropatilerinde daha önceden tanımlanmış bir yöntemdir. Periferik sinirlerin sık görülen tuzak nöropatileri daha önceden belirtilmiştir. **Gereç ve Yöntem:** Bu yazıda ulnar sinirin nadir görülen bir sıkışması ve illustrative bir olguda ultrasonografik nörografi bulguları sunulmaktadır. **Olgu:** Beyin Cerrahisi Kliniğine ulnar sinir tuzak nöropatisi bulgularıyla başvurmuştur. **Bulgular:** Elektrofizyolojik muayene ulnar sinirin ulnar kanala girmeden önce sıkışma bulgularını vermiştir. Ameliyattan önce hasta ultrasonografik nörografi yöntemiyle incelenmiştir. Ultrasonografik nörografi incelemesi ulnar sinirin ulnar kanala girmeden 5 cm önce sıkışma bulgularını göstermiştir. Hasta ameliyat edilmiştir. Ameliyat bulguları ultrasonografik nörografiden elde olunan bulgularla benzerlik göstermiştir. **Tartışma:** Bu yazıda klinik pratikte bu şekildeki patolojilerin gösterilmesinde ultrasonografik nörografinin rolü ile klinik ve ameliyat bulguları sunulmaktadır.

Anahtar Kelimeler

İntermusküler Bağ; Ulnar Sinir; Ultrasonografik Nörografi; Periferik Sinir Cerrahisi; Tuzak Nöropatisi

Abstract

Aim: Ultrasonographic neurography is a described method in the cases with peripheral nerve injury and entrapment. The usual entrapment of the peripheral nerves had been described previously. **Material and Method:** In this report it was presented the unusual entrapment of the ulnar nerve and the neurographic findings in an illustrative case. The case was admitted to our neurosurgery department with the symptoms of ulnar nerve entrapment. **Results:** Electrophysiologic examination revealed that ulnar nerve entrapment before entering ulnar nerve canal. We examined the patient by using ultrasound assisted neurographic examination before operation. Ultrasonographic neurography demonstrated ulnar nerve compression 5 cm proximal portion from its entrance into the ulnar nerve canal. The patient was operated. Operative findings were similar with those of ultrasonographic neurography. **Discussion:** In this report we present clinical and operative findings of this case including the role of ultrasonographic neurography in the demonstrating these type of pathologies in the clinical practice.

Keywords

Intermuscular Arcade; Ulnar Nerve; Ultrasonographic Neurography; Peripheral Nerve Surgery; Entrapment Neuropathy

DOI: 10.4328/JCAM.1354

Received: 25.10.2012 Accepted: 19.11.2012 Printed: 01.07.2014

J Clin Anal Med 2014;5(4): 291-3

Corresponding Author: Cengiz Çokluk, Ondokuzmayıs University Medical Faculty Department of Neurosurgery, samsun, Turkey.

T.: +90 3623121919/3086 F.: +90 3624576041 E-Mail: ccokluk@omu.edu.tr

Introduction

Neurological findings and electrodiagnostic tests are the gold standards in the diagnosing of peripheral nerve entrapments and making decision about the selection of treatment modality [1-3]. Intraoperative ultrasound has been used in the neurosurgical procedures, especially in the localising of cystic and solid lesions, for several years. Some previous studies had been conducted to evaluate peripheral nerves by ultrasound [4-8]. In these studies, the authors described normal and pathologic ultrasonographic appearance of peripheral nerves [4-8].

This clinical study was designed to evaluate the feasibility of presurgical and intraoperative ultrasound assisted neuroexamination in the localisation of entrapped field, determination of the type of the entrapment in a patient with entrapment neuropathy of ulnary nerve by an intermuscular arcade.

Material and Method

55 year-old man had been referred to our neurosurgery department with the symptoms of ulnary nerve entrapment. Electrophysiologic examination showed the ulnary nerve entrapment before entering its canal. We examined the patient by using ultrasound assisted neurographic examination before operation (Figure 1). Ultrasonographic neurography demonstrated that the ulnary nerve compressed at the point of 5 cm proximal to its entrance into the ulnar canal (Figure 1). The patient was operated. Operative findings showed the presence of intermuscular arcade compressed to ulnary nerve (Figure 2). Operative findings were similar with those of ultrasonographic neurography. The arcade was cut off by using a scissor. The chronical impression site on the nerve was inspected by using operative microscope after removing of intermuscular arcade (Figure 3). Postoperative period was uneventful. The patient was discharged after 3 days from the operation.

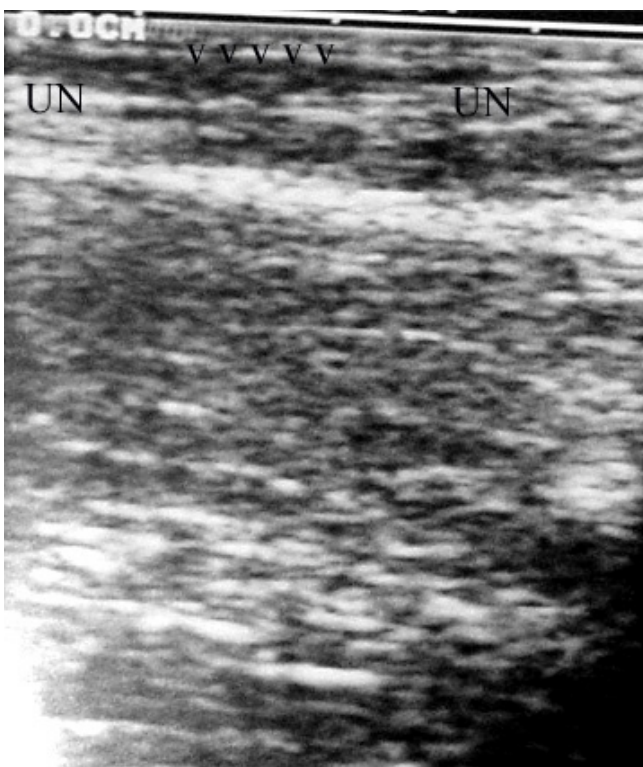


Figure 1. Ultrasonographic neurography shows ulnary nerve and compression site (UN: Ulnary nerve, Arrows show the compression site).

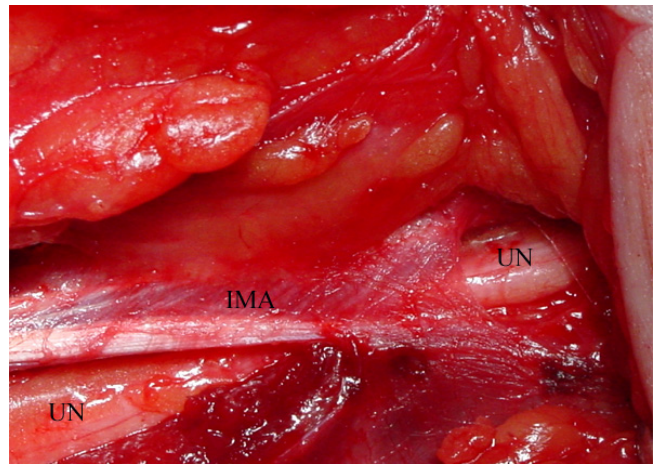


Figure 2. Intraoperative photo shows intermuscular arcade and ulnary nerve (IMA: Intermuscular arcade, UN: Ulnary nerve).

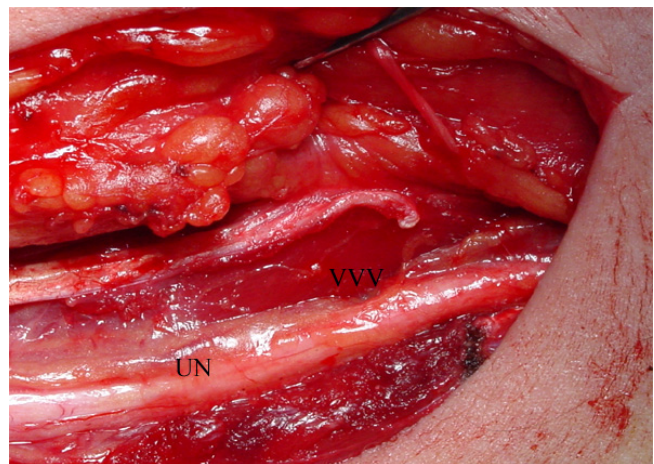


Figure 3. The appearance of compression site in the nerve (Arrows shows the compression site, UN: Ulnary nerve).

Discussion

Ulnar neuropathy at the elbow is the second most common entrapment neuropathy of the upper limb, next to carpal tunnel syndrome. The ulnar nerve entrapment is most frequently seen in the region of the retroepicondylar (ulnar) groove resulting from various pathological processes. Anatomically, the ulnary nerve travels from the axilla after emerging from the brachial plexus into the medial aspect of the anterior compartment of the arm. It then traverses the intermuscular (intercompartmental) septum, passes through the arcade of Struthers, and continues its path in the posterior aspect of the arm down to the elbow and submerges into the cubital tunnel posterior to the medial epicondyle [9]. The ulnary nerve may become entrapped at the arcade or across the intermuscular septum. Sir John Struthers, a whale anatomist, described the arcade in Scotland in 1854 [9].

Electrodiagnostic tests can precisely distinguish the severity of entrapment. Sometimes electrodiagnostic tests may not yield reliable information about the location of the entrapment site, because a variety of parameters may affect this examination [4]. In the same way, electrodiagnostic tests can not give any information about the position of the nerve, the presence of a neuroma and excessive scar tissue around the nerve. In this perspective, we need an image guided tool preoperative and intraoperative period in the surgical treatment of entrapment

neuropathies for precise localisation of entrapped site and determination of the type lesion. We theorized that sonographic neuroexamination may help us in the localization and type of the lesion. The electrodiagnostic test revealed that the entrapped site was located proximal of the ulnar canal. Sonographic neuroexamination showed the precise location of the entrapment. Our case demonstrated that ultrasonographic neuroexamination is a useful diagnostic test in the making-decision of the treatment of ulnary nerve neuropathy. Sonographic neuroexamination may also be used as an image guided tool during the surgical treatment of peripheral nerve entrapment neuropathy.

Competing interests

The authors declare that they have no competing interests.

References

1. Gentili F, Hudson AR, Midha R. Peripheral nerve injuries: Types, causes, and grading. In: Wilkins RH, Rengachary SS (eds). Neurosurgery. Vol 3. New York: McGraw-Hill, 1996: 3105-14.
2. Kline DG. Surgical repair of peripheral nerve injury. Muscle Nerve 1990; 13(9):843-52.
3. Kline DG, Hudson AR. Acute injuries of peripheral nerves. In: Youmans JR (ed) Neurological surgery Vol 4. Philadelphia: W. B. Saunders Company, 1990:p.2423-510.
4. Peer S, Bodner G, Meirer R, Willeit J, Piza-Katzer H. Examination of postoperative peripheral nerve lesions with high-resolution sonography. AJR 2001;177(2):415-9.
5. Martinoli C, Bianchi S, Dahmane M, Pugliese F, Bianchi-Zamorani MP, Valle M. Ultrasound of tendons and nerves. Eur Radiol 2002;12(1):44-55.
6. Martinoli C, Bianchi S, Giovagnorio F, Pugliese F. Ultrasound of the elbow. Skeletal Radiol 2001;30(11):605-14.
7. Martinoli C, Serafini G, Bianchi S, Bertolotto M, Gandolfo N, Derchi LE. Ultrasonography of peripheral nerves. J Peripher Nerv Syst 1996; 1(3):169-78.
8. Peer S, Kovacs P, Harpf C, Bodner G. High-resolution sonography of lower extremity peripheral nerves. Anatomic correlation and spectrum of disease. J Ultrasound Med 2002;21(3):315-22.
9. von Schroeder HP, Schecker LR. Redefining the arcade of Struthers. J Hand Surg 2003;28(6):1018-21.